

# Endometriosis

---

*A Guide for Patients*



PATIENT INFORMATION SERIES

*Published by the American Society for Reproductive Medicine under the direction of the Patient Education Committee and the Publications Committee. No portion herein may be reproduced in any form without written permission. This booklet is in no way intended to replace, dictate or fully define evaluation and treatment by a qualified physician. It is intended solely as an aid for patients seeking general information on issues in reproductive medicine.*

*Copyright © 2016 by the American Society for Reproductive Medicine*

# Endometriosis

## A Guide for Patients

Revised 2016

*A glossary of italicized words is located at the end of this booklet.*

### INTRODUCTION

Endometriosis is a common condition that affects women during the reproductive years. Women with endometriosis may experience infertility, pelvic pain, or both. This booklet will describe options for diagnosing and treating pain or infertility that may be attributed to endometriosis.

### What Is Endometriosis?

Endometriosis occurs when tissue similar to the uterine lining (*endometrium*) grows outside the uterus, typically in the pelvis. This endometrial tissue causes changes that may lead to pain and infertility.

Figure 1

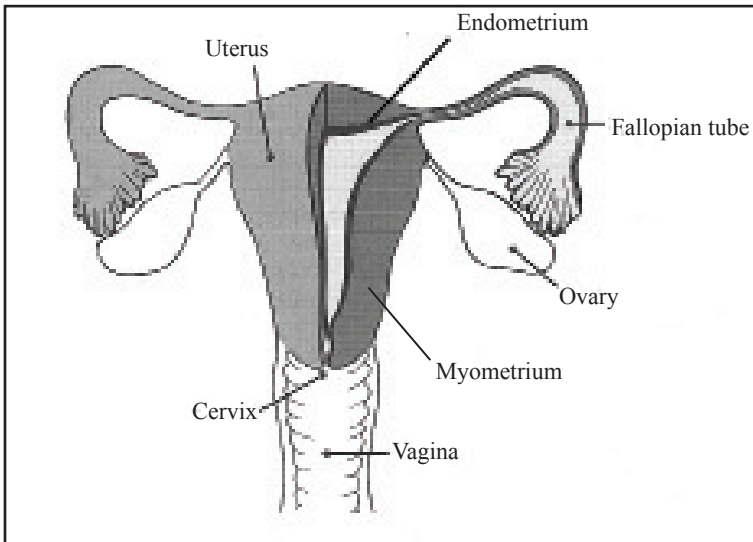


Figure 1. The Female Reproductive Organs. A basic knowledge of these organs and their functions is helpful to understanding endometriosis.

Experts do not know why some women develop endometriosis. During each menstrual period, most of the uterine lining and blood are shed through the *cervix* and into the vagina. However, some of this tissue enters the pelvis through the *fallopian tubes*. One theory is that women who develop endometriosis simply may be unable to clear these cells from the pelvis.

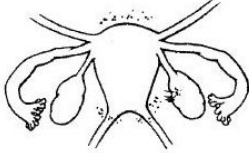
Endometriosis implants initially look like small, flat patches, blebs, or flecks sprinkled on the surface of the pelvic organs or on the lining of the pelvis, appearing clear, white, brown, red, black, or blue. The severity, course, and associated symptoms or problems of endometriosis are highly unpredictable. Some women may have a few endometriosis implants on the surface of the pelvic lining or organs, or, alternatively, the implants may invade the pelvic lining and grow as nodules. Endometriosis may grow on the surface of the *ovary* or form inside the ovary and develop a blood-filled cyst called an *endometrioma*, or a “chocolate cyst.” Chocolate cysts are so named because over time the blood they contain darkens to a deep reddish-brown color. These cysts may be as small as a pea or grow to be larger than a grapefruit. Endometriosis may irritate pelvic tissue and produce internal scar tissue called *adhesions*. These adhesions can bind the pelvic organs together, cover them entirely, and/or involve nearby intestines. The adhesions may keep fallopian tubes from picking up the egg from the ovary during *ovulation*. Endometriosis rarely may grow into the walls of the intestine or into tissue between the vagina and the rectum.

Up to 10% of all women have endometriosis. Endometriosis may be found in 24% to 50% of women who experience infertility and in more than 20% who have chronic pelvic pain. Many women who have endometriosis experience few or no symptoms. Some women experience severe menstrual cramps, chronic pelvic pain, or painful intercourse. In others, infertility may be the only symptom of endometriosis. Often, endometriosis is diagnosed when a woman has pelvic surgery because of a persistent ovarian cyst or other reasons. Endometriosis can affect women who have had children and can occur in teenagers and young women. Some specialists feel that endometriosis is more likely to be found in women who have never been pregnant.

Endometriosis can be classified based on a point system, into one of four progressive stages (I-minimal, II-mild, III-moderate, and IV-

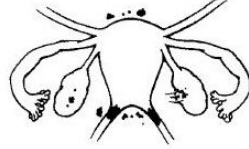
Figure 2

**STAGE I (MINIMAL)**



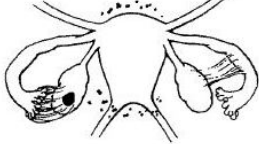
PERITONEUM			
Superficial Endo	1-3cm	2	
Right OVARY			
Superficial Endo	<1cm	1	
Filmy Adhesions	1/3	1	
TOTAL POINTS		4	

**STAGE II (MILD)**



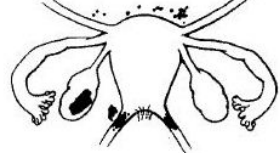
PERITONEUM			
Deep Endo	>3cm	6	
Right OVARY			
Superficial Endo	<1cm	1	
Filmy Adhesions	<1/3	1	
Left OVARY			
Superficial Endo	<1cm	1	
TOTAL POINTS		9	

**STAGE III (MODERATE)**



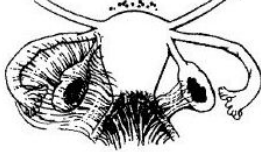
PERITONEUM			
Deep Endo	>3cm	6	
CULDESAC			
Partial Obliteration		4	
Left OVARY			
Deep Endo	1-3cm	16	
TOTAL POINTS		26	

**STAGE III (MODERATE)**



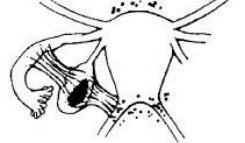
PERITONEUM			
Superficial Endo	>3cm	4	
Right TUBE			
Filmy Adhesions	<1/3	1	
Right OVARY			
Filmy Adhesions	<1/3	1	
Left TUBE			
Dense Adhesions	<1/3	16*	
Left OVARY			
Deep Endo	1-3cm	4	
Dense Adhesions	<1/3	4	
TOTAL POINTS		30	

**STAGE IV (SEVERE)**



PERITONEUM			
Deep Endo	>3cm	6	
CULDESAC			
Complete Obliteration		40	
Right OVARY			
Deep Endo	1-3cm	16	
Dense Adhesions	<1/3	4	
Left TUBE			
Dense Adhesions	>2/3	16	
Left OVARY			
Deep Endo	1-3cm	16	
Dense Adhesions	>2/3	16	
TOTAL POINTS		114	

**STAGE IV (SEVERE)**



PERITONEUM			
Superficial Endo	>3cm	4	
Left OVARY			
Deep Endo	<1cm	32**	
Dense Adhesions	<1/3	8**	
Left TUBE			
Dense Adhesions	<1/3	8**	
TOTAL POINTS		52	

\*Point assignment changed to 16

\*\* Point assignment doubled

severe) depending on location, extent, and depth of endometriosis implants; presence and severity of adhesions; and presence and size of ovarian endometriomas (Figure 2). Most women have minimal or mild endometriosis, which is characterized by superficial implants and mild adhesions. Moderate and severe endometriosis are characterized by chocolate cysts in the ovaries and more severe adhesions. Although the stage of endometriosis does not always correlate with the presence or severity of symptom, infertility is very likely with stage IV endometriosis (Figure 2).

## **SYMPTOMS OF ENDOMETRIOSIS**

### ***Menstrual Cramps***

Many women experience mild menstrual cramps, which are considered normal. When cramping is more severe it is called *dysmenorrhea* and may be a symptom of endometriosis or other types of pelvic pathology such as uterine fibroids or *adenomyosis*. Severe cramping may occasionally cause nausea, vomiting, or diarrhea. *Primary dysmenorrhea* occurs during the early years of menstruation, tends to improve with age, and usually is not related to endometriosis. *Secondary dysmenorrhea* occurs after the early years of menstruation and may continue to worsen with age. This may be a warning sign of endometriosis, although some women with endometriosis feel no cramping at all and many women with dysmenorrhea do not have endometriosis.

### ***Painful Intercourse***

Endometriosis can cause pain during or after intercourse, a condition known as *dyspareunia*. Deep penetration can produce pain in an ovary bound by scar tissue to the top of the vagina. Pain also may be caused by bumping against a tender nodule of endometriosis behind the *uterus* or on the ligaments that connect the cervix to the *sacrum*.

### ***Infertility***

There is a large body of evidence that demonstrates an association between endometriosis and infertility. Endometriosis can be found in up to 50% of infertile women. Infertility patients with untreated mild endometriosis conceive on their own at a rate of 2% to 4.5% per month, compared with a 15% to 20% monthly fertility rate in normal couples. Of note, treating mild endometriosis is not felt to meaningfully improve pregnancy rates compared with no treatment or medical treatment. Infertile women with moderate and severe endometriosis have monthly pregnancy rates of less

than 2%. For these reasons, fertility drugs and possible in vitro fertilization (IVF) are often recommended for women with endometriosis who have been unsuccessful in their attempts to become pregnant. Even though endometriosis is associated strongly with infertility, not all women who have endometriosis are infertile. For example, many women undergoing tubal sterilization procedures are noted to have endometriosis, suggesting that their endometriosis did not prevent them from having children.

A cause-and-effect relationship between endometriosis and reduced fertility is presumed but not proven. It is not known how minimal and mild endometriosis reduces fertility when there are no adhesions. It is presumed that endometriosis alters the pelvic environment in subtle but important ways. Theories include inflammation, altered immune system, hormonal changes, abnormal function of the fallopian tube, or impaired fertilization and implantation. It is easier to understand how moderate or severe endometriosis reduces fertility, since major pelvic adhesions, when present, may prevent the release of eggs and prevent the fallopian tube's ability to pick up eggs during ovulation.

## **HOW IS ENDOMETRIOSIS DIAGNOSED?**

Endometriosis cannot be definitively diagnosed by symptoms alone. Your physician may suspect endometriosis if you are having fertility problems, severe menstrual cramps, pain during intercourse, or chronic pelvic pain. It also may be suspected when there is a persistent ovarian cyst. Endometriosis is more likely to be found if a close family member like a mother or sister has the condition. Remember, however, that many women with endometriosis have no symptoms at all.

### ***Pelvic Exam***

Certain findings of a pelvic examination may lead your physician to suspect endometriosis. During a combined vaginal and rectal exam, a tender nodule may be felt behind the cervix, or the uterus may lack mobility because of adhesions and scar tissue. One or both ovaries may be enlarged or fixed in position. Rarely, endometriosis implants may be visible in the vagina or the cervix. Although your physician may suspect endometriosis based on your history and pelvic exam, surgery is needed to truly confirm the diagnosis.

### ***Laparoscopy***

*Laparoscopy* is an outpatient surgical procedure that enables the physician to see the pelvic organs and look for endometriosis and potentially treat

it surgically at the same time. During laparoscopy, a thin camera called a *laparoscope* is inserted into the abdomen through a small incision near the navel. The laparoscope allows the surgeon to see the surface of the uterus, fallopian tubes, ovaries, and other pelvic organs. For more information on laparoscopy, please see the American Society for Reproductive Medicine (ASRM) booklet titled *Laparoscopy and Hysteroscopy*.

The extent of endometriosis is evaluated during laparoscopy. A clinical staging system is used to describe the extent of endometriosis, adhesions, and endometrioma cysts in the ovary (Figure 2). A score of 1-15 indicates minimal or mild endometriosis and a score of 16 or higher indicates moderate or severe disease. The staging system, however, does not correlate well with a woman's chance of conceiving with fertility treatment or the degree of pain that she experiences.

Your physician may decide to treat your endometriosis during the laparoscopy. Additional small incisions allow your physician to insert surgical instruments. The endometriosis lesions may be removed or destroyed and ovarian cysts may be removed. During laparoscopy, your doctor can determine if your fallopian tubes are open by injecting dye through the cervix into the uterus. If the tubes are open, the dye will flow out the ends of the fallopian tubes. If they are blocked, it may be possible to correct that during this surgery.

### ***Other Diagnostic Procedures***

In special cases, your doctor may use special imaging techniques such as *ultrasound*, *computerized tomography (CT) scan*, or *magnetic resonance imaging (MRI)* to gather more information about your pelvis. These procedures can identify cysts and help characterize the fluid within an ovarian cyst, although an endometriotic cyst and a normal *corpus luteum* cyst may have a similar appearance. These tests may be useful when evaluating women experiencing infertility and/or chronic pelvic pain and may help to clarify findings found during a physical exam.

### **TREATMENT OF PAIN**

Your doctor will consider your symptoms, physical examination, test results, and your goals and concerns before advising treatment. Women with mild symptoms may benefit from lifestyle changes or require no treatment at all. Hormonal therapy may be suggested when pain interferes with family, work, or daily activities. These therapies usually reduce pelvic



pain and dyspareunia in more than 80% of women in whom endometriosis is diagnosed. Since several effective treatments are available, the choice is made based on side effects and cost. Hormonal treatments are not effective for large ovarian endometriomas, and surgery is necessary. Surgery also may be indicated when medical treatment is unsuccessful or when medical conditions prohibit the use of hormone treatments.

### ***Lifestyle Modifications***

Some women have found that their pain is improved by exercise and relaxation techniques. Natural supplements have not been shown to reduce endometriosis-related pain, but over-the-counter, nonsteroidal, anti-inflammatory medications, like ibuprofen and naproxen, may help reduce painful menstrual cramps. When painful intercourse is a problem, changing positions may help decrease the pain caused by deep penetration. In spite of these measures, further medical treatment is frequently needed.

### ***Hormonal Contraceptives***

Birth control pills often reduce the menstrual cramping and pelvic pain that may be associated with endometriosis. No one type of pill appears to be better than any other when treating endometriosis symptoms.

Birth control pills may be prescribed continuously, without pausing for menstrual periods, to women with endometriosis. Side effects of this approach include fluid retention and irregular spotting or bleeding. Serious side effects of birth control pills are very rare and include stroke, vascular problems, and heart disease. It also should be noted that endometriosis may be diagnosed in women taking birth control pills, and that birth control pills have never been shown to prevent the development of endometriosis. No data are currently available concerning the effect of transdermal contraceptive patches and vaginal contraceptive rings upon endometriosis.

### ***Progestins***

Progestins are synthetic medications that have *progesterone*-like activity upon the endometrium. Many *progestins* have been demonstrated to reduce endometriosis-associated pelvic pain. The most common side effects of progestin therapy are irregular uterine bleeding, weight gain, fluid retention, breast tenderness, headaches, nausea, and mood changes, and occasionally depression. Progestins are typically less expensive than other medications and may be prescribed as pills, injections, or the levonorgestrel-containing intrauterine contraceptive devices (IUDs).

### ***Gonadotropin-releasing Hormone (GnRH) Analogs***

*GnRH analogs*, particularly GnRH agonists, are medications that cause *estrogen* levels to reversibly fall to menopausal levels so that menstruation does not occur. These drugs are highly effective for painful endometriosis. Side effects include menopausal symptoms, including hot flashes, vaginal dryness, and loss of calcium from the bones. They are also costly

These medications are usually given for 6 months. Low-dose estrogen-progestin hormone therapy or progestins alone may be added to prevent bone loss when prolonged treatment is needed or if menopausal symptoms are severe. Calcium supplementation and exercise are recommended to reduce the loss of bone density that occurs with therapy. Most bone density loss is temporary and is regained after treatment is stopped. All preparations are equally effective and differ mainly in cost and side-effect profiles.

### ***Danazol***

*Danazol*, a medication that is similar to male hormones, also is highly effective for pain due to endometriosis. Common side effects may include water retention, acne, irregular vaginal bleeding, muscle cramps, and reduced breast size. Uncommon but irreversible side effects include deepening of the voice and growth of facial or body hair. Danazol is not often used to treat endometriosis currently because medications such as GnRH agonists are equally effective and have a more favorable side-effect profile than danazol.

### ***Surgery for Pain***

Surgical treatment of endometriosis often is performed when endometriosis is diagnosed during laparoscopy. Laparoscopy is a procedure in which a lighted telescope is placed through an incision below the navel to view the pelvic cavity. During laparoscopy, the physician may remove adhesions, endometriotic *nodules*, and ovarian cysts. Laparoscopy often is used to treat recurrent endometriosis when the goal is to preserve future fertility. Sometimes the severity of endometriosis is such that major surgery is advised to remove endometriosis and adhesions. For treating pain and prevention of recurrent cysts, removal of the entire ovarian cyst with its wall is superior to merely draining the endometriotic cyst.

Overall, fertility-preserving endometriosis surgery improves pain for 60% to 80% of women. After surgery, long-term medical therapy for

management of endometriosis-related pain is usually necessary because 40% to 80% of women experience recurrent pain symptoms within 2 years of surgery. If the medication is stopped, recurrent symptoms occur within 5 to 10 years in more than 50% of women.

Hysterectomy (removal of the uterus) with removal of the ovaries can be used to definitively treat endometriosis after childbearing is completed. This surgery provides final relief from endometriosis-related pain in more than 90% of women. If one or both ovaries are preserved, there may be a greater chance that symptoms will recur, and additional surgery will be required. If needed, low-dose hormone therapy (estrogens or progestins) reduces hot flashes and menopausal symptoms that occur after hysterectomy when the ovaries are removed.

### ***Pregnancy***

Although the benefit is often temporary, endometriosis and its symptoms often regress during pregnancy. The hormonal environment produced by pregnancy may inhibit the condition.

### ***Team Approach to Pain***

Some women continue to experience severe pain in spite of hormonal and surgical treatments. When pain persists, a multidisciplinary “team” approach may be helpful. This approach combines the expertise of a group of specialist physicians, including mental health specialists, counselors, and physical therapists, often at a “pain center.” Nerve blocks, acupuncture, or other treatments may be beneficial.

### ***Investigational Drug Treatments for Endometriosis***

A number of new drugs are under research and development for endometriosis. Anti-progestins, such as mifepristone and onapristone, have had success in small studies. These medications work by modulating the estrogen and progesterone receptors in endometriosis *implants* and causing atrophy of endometriosis. Selective estrogen receptor modulators (SERMs) may be effective by virtue of their anti-estrogen effect. Raloxifene is the SERM that currently shows some promise. Aromatase inhibitors—medications that inhibit aromatase, an enzyme that is required for estrogen synthesis—have had success in small studies and case reports. Anastrozole and letrozole are two examples of aromatase inhibitors undergoing investigation. Leukotriene antagonists theoretically will improve *dysmenorrhea* by modulating the activity of leukotrienes,

immune chemicals that contribute to inflammation and pain. Other immune modulators are under investigation in animal models as potential therapies for endometriosis. These include loxoribine, levamisole, interleukin-12, and interferon-alpha-2b.

## **TREATMENT OF INFERTILITY**

The entire infertility evaluation should be completed before considering treatment for endometriosis. For infertile women with suspected minimal or mild endometriosis, a decision must be made whether to perform laparoscopy before starting treatments to enhance fertility. Although surgical treatment of low-stage endometriosis may improve fertility, the actual increase is fairly minimal. Clearly, factors such as a woman's age, duration of infertility, and pelvic pain must be considered. Other infertility factors may coexist and impact success rates and treatment outcome. If pain also is a concern, laparoscopy and surgical treatment may be prudent. In addition, laparoscopy and possible *laparotomy* (large incision) are recommended when moderate or severe endometriosis is suspected and no other cause of infertility has been found, especially if insurance coverage for in vitro fertilization (IVF) is not available.

### ***Surgery for Infertility***

Laparoscopic treatment of minimal and mild endometriosis has been associated with a small but significant improvement in pregnancy rates. In a large study, 29% of women who had their endometriosis treated conceived within 9 months, in contrast to only 17% of women whose endometriosis was diagnosed but not treated during laparoscopy. Although this is a modest treatment benefit (going from approximately a 2.4% chance of getting pregnant in any one cycle to 4.7%), it suggests that there is a period of enhanced fertility after laparoscopic treatment of endometriosis. Ultimately, many physicians feel that if only minimal endometriosis is suspected, performing laparoscopy for this reason only may not be worthwhile. However, if laparoscopy is performed and minimal endometriosis is seen, treatment may be worthwhile. Treatment of moderate and severe endometriosis by laparoscopy and/or laparotomy increases pregnancy rates for women in whom no other causes of infertility have been found. There is no evidence that the outcome is improved by any specific method used to treat endometriosis, such as electrosurgery, laser, excision, or ablation.

### ***Medical Therapy for Infertility***

Whereas medical therapy is effective for relieving pain associated with endometriosis, there is no evidence that medical treatment of endometriosis by birth control pills, progestins, GnRH analogs, or danazol improves fertility. Furthermore, surgery combined with medical therapy has not been shown to enhance fertility. Instead, medical treatment before, after, or instead of surgery may delay unnecessarily further fertility therapy and attempts at conceiving. Nevertheless, these treatments are often effective in reducing pelvic pain and painful intercourse associated with endometriosis. Therefore, hormonal suppression may improve comfort and sexual activity in infertile women with endometriosis and pelvic pain, thereby improving their ability and desire to attempt to become pregnant after the completion of the treatment.

### ***Expectant Management***

A “watchful waiting” approach, also called *expectant management*, may be an option for younger women after surgery for endometriosis. Up to 40% of women may conceive during the first 8 to 9 months after laparoscopic management of minimal or mild endometriosis. Fertility-enhancing treatments may be offered as an alternative to expectant management or if pregnancy fails to occur within a reasonable time frame. A woman’s age is an important factor in deciding upon specific treatment. Women aged 35 years and older have lower fertility potential and higher chances of miscarriage. The decrease in fertility due to endometriosis and age may be additive. Therefore, more aggressive fertility treatments seem reasonable in older women with endometriosis. Watchful waiting is not a good option for women with infertility associated with severe endometriosis.

## **FERTILITY-ENHANCING TREATMENTS**

### ***Controlled Ovarian Stimulation and Intrauterine Insemination***

Several studies have shown that fertility is enhanced in women with minimal or mild endometriosis by *controlled ovarian stimulation (COS)* with *intrauterine insemination (IUI)*. This treatment also is called *superovulation* with IUI. Without treatment, women with minimal/mild endometriosis-related infertility have spontaneous pregnancy rates of 2% to 4.5% per month. The monthly pregnancy rate with intrauterine insemination alone for endometriosis is approximately 5%, and it is approximately 4% to 7% per month for *clomiphene citrate*, *human menopausal gonadotropin (hMG)*, or *follicle-stimulating hormone (FSH)* injections when used without IUI. However, clomiphene plus IUI

improves the monthly pregnancy rate to approximately 9% to 10%, at least for the first four treatment cycles. Human menopausal hormone (hMG) or FSH plus IUI improves the success to 9% to 15% per month. COS with clomiphene plus IUI carries a 5% to 15% risk of twins. Multiple pregnancy and ovarian hyperstimulation are risks associated with hMG IUI therapy.

### ***Assisted Reproductive Technology***

In general, couples diagnosed with endometriosis have success rates with *assisted reproductive technology (ART)* procedures such as *in vitro fertilization and embryo transfer (IVF-ET)* that are similar to those for couples with other causes of infertility. Success rates for ART procedures vary greatly depending on a woman's age. Nationally, live-birth rates for IVF-ET are approximately 40% for women under age 35, 31% from ages 35 to 37, 21% from ages 38 to 40, and about 11% between 41 and 42 (2013 data). IVF-ET is the most effective treatment for moderate or severe endometriosis, particularly if surgery fails to restore fertility. Some physicians recommend long-term pretreatment with GnRH analogs before starting IVF in women with severe endometriosis, since some, but not all, studies have shown that this approach may improve IVF-ET outcomes.

### **CONCLUSION**

Endometriosis affects millions of women throughout the world. It demands professional attention, especially when fertility is impaired or pain affects lifestyle. Endometriosis may be a lifelong problem, because pain and endometriomas may recur after therapy. This condition has the potential to disrupt quality of life and cause significant emotional distress. A woman's age, duration of infertility, pelvic pain, and stage of endometriosis are taken into account when formulating an infertility treatment plan. Choosing a qualified specialist—one who is familiar with the latest developments in management of endometriosis—is your best strategy. The physician you choose will recommend the most appropriate course of treatment based on your personal situation.

# GLOSSARY

**Adenomyosis.** A benign (non-cancerous) invasion of endometrial tissue into the uterine wall.

**Adhesions.** Bands of fibrous tissues that bind the abdominal or pelvic organs together.

**Assisted reproductive technology (ART).** A fertility-enhancing procedure that most commonly refers to in vitro fertilization and embryo transfer. Also includes procedures in which unfertilized eggs and sperm are placed into the fallopian tube (gamete intrafallopian transfer - GIFT), or fertilized eggs are placed into the fallopian tube (zygote intrafallopian transfer - ZIFT).

**Cervix.** The lower part of the uterus that opens into the vagina.

**Clomiphene citrate.** A fertility pill used to promote ovulation, often of more than one egg.

**Computerized tomography (CT) scan.** A technique of x-ray imaging that creates a 3-dimensional image.

**Controlled ovarian stimulation (COS).** Treatment with clomiphene, human menopausal gonadotropin, or follicle-stimulating hormone injections to cause more than one egg to develop and release during ovulation.

**Corpus luteum.** A yellow body in the ovary that forms from a follicle after ovulation; the follicle has matured, ruptured, and released its egg. The corpus luteum produces progesterone and estrogen during the second half of a normal menstrual cycle.

**Danazol.** A synthetic, weak male hormone that blocks ovulation and suppresses estrogen levels; used to treat endometriosis.

**Dysmenorrhea.** Painful menstrual cramps.

**Dyspareunia.** Painful intercourse; sometimes a symptom of endometriosis.

**Endometrioma.** A blood-filled “chocolate” cyst that can occur when endometriosis tissue develops in the ovary.

**Endometrium.** The lining of the uterus that is shed each month during menstruation.

**Estrogen.** A hormone produced mainly by the ovaries. Estrogen largely is responsible for stimulating the endometrium to thicken and prepare for pregnancy during the first half of the menstrual cycle.

**Expectant management.** Period of “watchful waiting” without active treatment.

**Fallopian tubes.** A pair of organs attached to the uterus. The egg travels from the ovary to the uterus through a narrow passageway inside the tubes, and natural fertilization occurs in the fallopian tubes.

**Follicle.** A small, spherical cyst located under the surface of the ovary. It contains the egg, the surrounding layer of cells, and fluid. The follicle

enlarges during the first half of the menstrual cycle. At ovulation, the mature follicle releases the egg.

**Follicle-stimulating hormone (FSH).** A hormone that stimulates growth of the follicle. May be used as a fertility injection to promote ovulation, often of more than one egg.

**GnRH analogs.** Synthetic chemicals similar to gonadotropin-releasing hormone, the natural hormone that prompts the pituitary gland to stimulate the ovaries to produce estrogen and progesterone. Prolonged use of GnRH analogs causes menopausal levels of estrogen.

**Human menopausal gonadotropin (hMG).** A fertility injection used to promote ovulation, often of more than one egg.

**Implants.** Small, flat patches of endometrial-like cells growing outside their normal location.

**In vitro fertilization and embryo transfer (IVF-ET).** A procedure in which eggs are fertilized in a laboratory and one or more embryo(s) is placed into the uterus.

**Intrauterine insemination (IUI).** An office procedure in which prepared sperm are placed into the uterus.

**Laparoscope.** A thin camera used to inspect the organs in the pelvis and abdomen.

**Laparoscopy.** A procedure in which a surgeon inserts a laparoscope through a small incision in or below the navel. This allows the doctor to inspect the uterus, fallopian tubes, ovaries, and other organs in the pelvis and abdomen. Additional incisions may be made for inserting surgical instruments.

**Laparotomy.** A procedure in which a surgeon makes an incision in the abdomen, usually several inches long, in order to treat conditions such as extensive endometriosis.

**Magnetic resonance imaging (MRI).** A diagnostic imaging procedure that absorbs energy from high frequency radio waves.

**Nodules.** Penetrating knot-like collections of endometriosis.

**Ovary.** One of two female glands that contains eggs and produces estrogen and progesterone.

**Ovulation.** Release of the egg from the ovary.

**Primary dysmenorrhea.** Pain associated with menstrual periods that decreases with age.

**Progesterone.** An ovarian hormone secreted by the corpus luteum during the second half of the menstrual cycle.

**Progestin.** A synthetic hormone that is similar to progesterone.

**Sacrum.** The last vertebrae of the spinal column; the base of the spine.



***Secondary dysmenorrhea.*** Pain associated with menstrual periods that begins later in a woman's reproductive life span. It may be due to an abnormal condition such as endometriosis or infection.

***Superovulation.*** Treatment with clomiphene, human menopausal gonadotropin, or follicle-stimulating hormone injections to cause more than one egg to develop and release during ovulation.

***Ultrasound.*** A technology that uses high-frequency sound waves to form an image of internal organs.

***Uterus.*** The muscular organ in which a pregnancy develops.

***For more information on this and other reproductive health topics visit [www.ReproductiveFacts.org](http://www.ReproductiveFacts.org)***



***Let Us Know What You Think!***

***Email your comments on this booklet to [asrm@asrm.org](mailto:asrm@asrm.org).***

***In the subject line, type "Attention: Patient Education Committee."***

# *Notes*





**AMERICAN SOCIETY FOR REPRODUCTIVE MEDICINE**  
1209 MONTGOMERY HIGHWAY  
BIRMINGHAM, ALABAMA 35216-2809  
(205) 978-5000 • [ASRM@ASRM.ORG](mailto:ASRM@ASRM.ORG)

**PATIENT SITE: [WWW.REPRODUCTIVEFACTS.ORG](http://WWW.REPRODUCTIVEFACTS.ORG)**  
**MEMBER SITE: [WWW.ASRM.ORG](http://WWW.ASRM.ORG)**